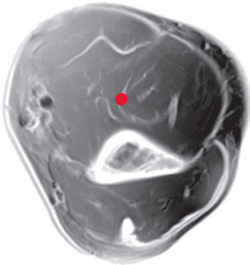


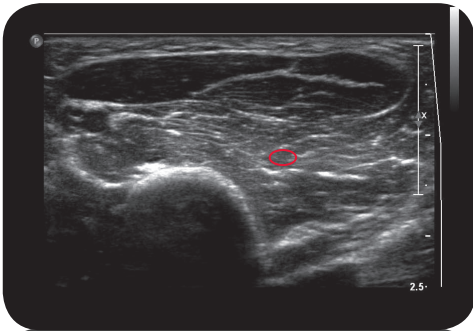
brachialis

\*\*\*

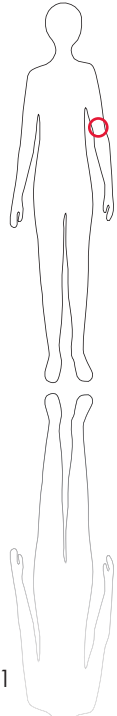
Cross Section



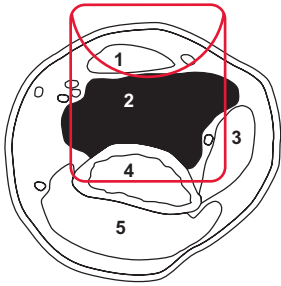
M R I



U l t r a s o u n d



101



L e g e n d

- 1: M. biceps brachii  
 2: M. brachialis 3: M. brachioradialis 4: Humerus  
 5: M. triceps brachii

O R I G I N

Distal anterior face of humerus.

I N S E R T I O N

T.u. and articular capsule

I n n e r v a t i o n

N. musculocutaneus (C5-C7)

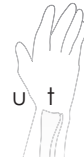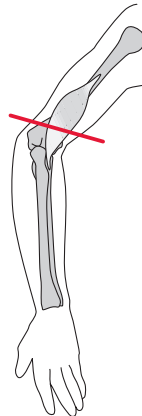
F u n c t i o n

Flexion of elbow, tonically stabilizes elbow joint

Control of Injection  
 Sonography, electrical stimulation, EMG

C o m m e n t

Strong flexor of elbow. Do not inject without injection of biceps because of important stabilizing effect on elbow joint.



S c o u t