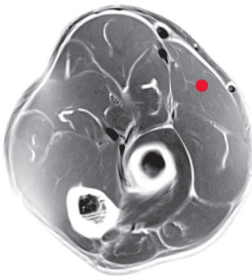


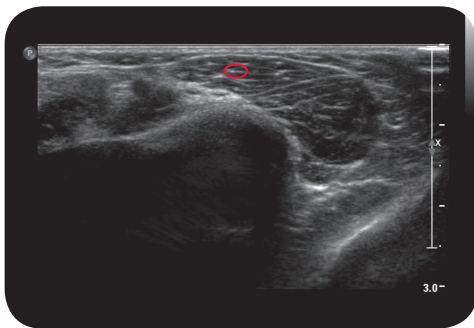
brachioradialis

**

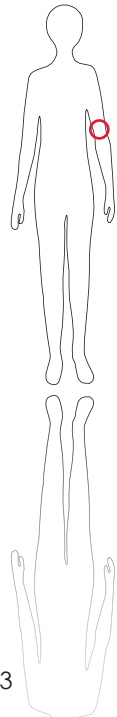
Cross Section



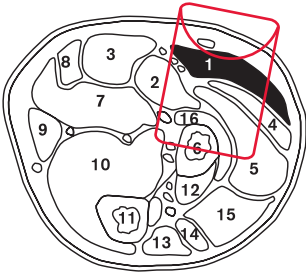
M R I



U l t r a s o u n d



103



L e g e n d

- 1: M. brachioradialis
 2: M. pronator teres
 3: M. flexor carpi radialis
 4: M. extensor carpi radialis longus
 5: M. extensor carpi radialis brevis
 6: Radius
 7: M. flexor digitorum superficialis
 8: M. palmaris longus
 9: M. flexor carpi ulnaris
 10: M. flexor digitorum profundus
 11: Ulna
 12: M. abductor pollicis longus
 13: M. extensor carpi ulnaris
 14: M. extensor digiti minimi
 15: M. extensor digitorum
 16: M. supinator

O r i g i n

Proximal two thirds of lateral supracondylar crest of humerus, lateral intermuscular septum of arm

I n s e r t i o n

Styloid process of radius

I n n e r v a t i o n

N. radialis (C5-C6)

F u n c t i o n

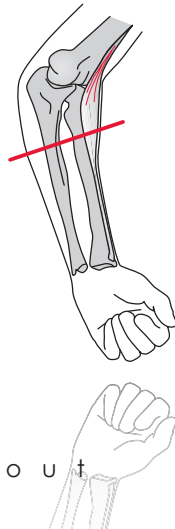
Strong flexor of elbow, important for fast movements

C o n t r o l o f I n j e c t i o n

Palpation, Sonography

C o m m e n t

Rather small elbow flexor, 1-2 injection sites.



S c o u t