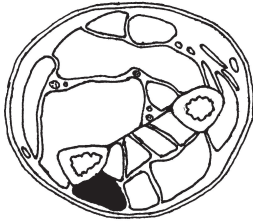
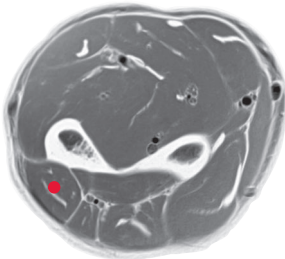


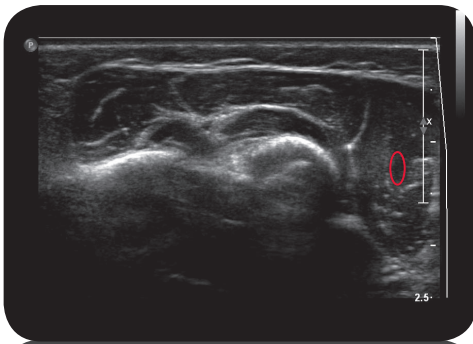
extensor carpi ulnaris



Cross Section

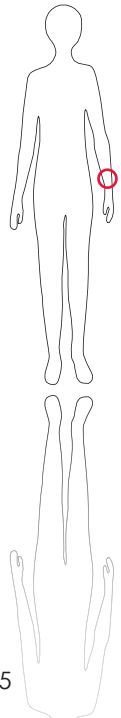


M R I

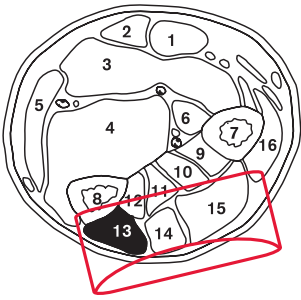


U l t r a s o u n d

*



125



L e g e n d

1: M. flexor carpi radialis
 2: M. palmaris longus 3: M. flexor digitorum superficialis 4: M. flexor digitorum profundus 5: M. flexor carpi ulnaris 6: M. flexor pollicis longus 7: Radius 8: Ulna 9: M. abductor pollicis longus 10: M. extensor pollicis brevis 11: M. extensor carpi pollicis longus 12: M. extensor indicis 13: M. extensor carpi ulnaris 14: M. extensor digiti minimi 15: M. extensor digitorum 16: M. extensor carpi radialis brevis

O r i g i n

Medial epicondyle of humerus

I n s e r t i o n

Base of second and third metacarpal bone

I n n e r v a t i o n

N. medianus (C6-C8)

F u n c t i o n

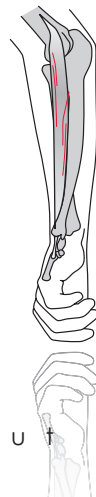Palmar extension and ulnar abduction of wrist joint.

C o n t r o l o f I n j e c t i o n

Sonography, electrical stimulation

C o m m e n t

Rare indication. Can be involved in extension deformities, 1-2 injection sites.



S c o u t