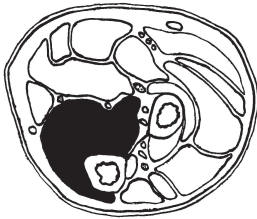
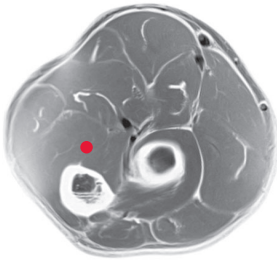


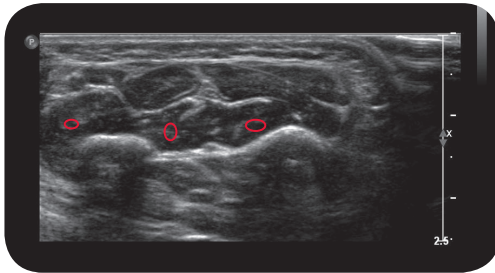
# flexor digitorum profundus



Cross Section

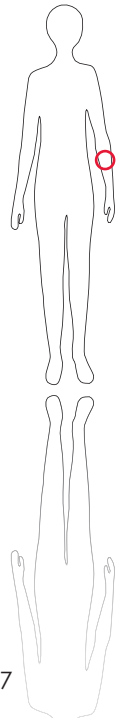


M R I

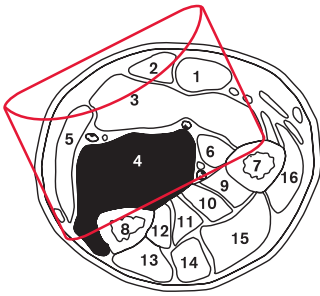


U l t r a s o u n d

\*\*\*



117



### L e g e n d

- 1: M. flexor carpi radialis
- 2: M. palmaris longus
- 3: M. flexor digitorum superficialis
- 4: M. flexor digitorum profundus
- 5: M. flexor carpi ulnaris
- 6: M. flexor pollicis longus
- 7: Radius
- 8: Ulna
- 9: M. abductor pollicis longus
- 10: M. extensor pollicis brevis
- 11: M. extensor pollicis longus
- 12: M. extensor indicis
- 13: M. extensor carpi ulnaris
- 14: M. extensor digiti minimi
- 15: M. extensor digitorum
- 16: M. extensor carpi radialis brevis

### O r i g i n

Proximal three quarters of palmar surface and medial area of ulna, interosseous membrane, antebrachial fascia

### I n s e r t i o n

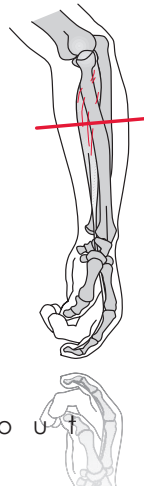
Base of second to fifth distal phalanges

I n n e r v a t i o n  
N. medianus, N. ulnaris  
(C7-T1)

F u n c t i o n  
Flexes all joints of second to fifth fingers, palmar flexion of wrist joint

C o n t r o l o f I n j e c t i o n  
Sonography, electrical stimulation

C o m m e n t  
Inject from the volar (i.e. flexor) side of the proximal ulna. With the help of above control techniques it is possible to differentiate between fascicles for second and third fingers and between fascicles for fourth and fifth fingers. 2-4 injection sites, one per fascicle.



S c o u t