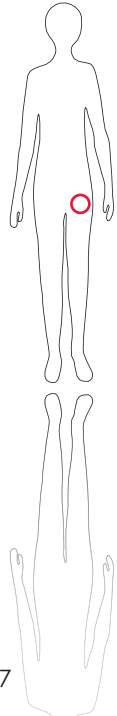
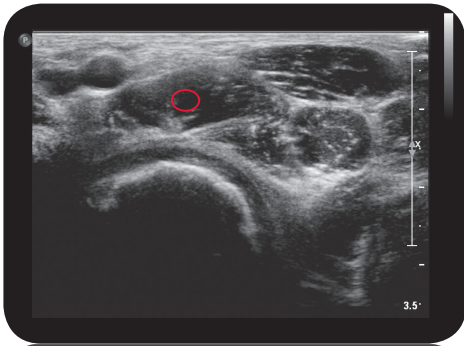
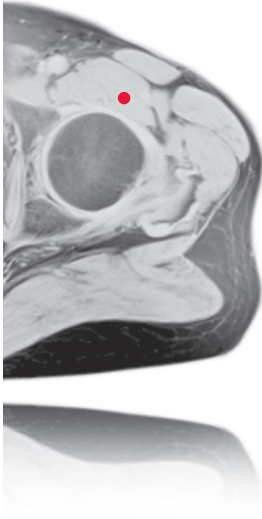
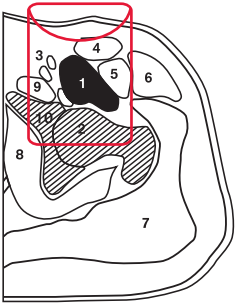


iliopsoas - m. iliacus





L e g e n d

1: M. iliopsoas 2: Caput femoris 3: A./V./N. femoris 4: M. sartorius 5: M. rectus femoris 6: M. tensor fascia latae 7: M. gluteus medius et maximus 8: M. obturatorius internus 9: M. pectineus 10: Fossa acetabuli

O r i g i n
Fossa iliaca; base of sacrum

I n s e r t i o n
Trochanter minor femoris

I n n e r v a t i o n
Plexus lumbalis (L1-L4)

F u n c t i o n
Flexion, abduction and external rotation of hip joint

Control of Injection
Sonography, EMG

C o m m e n t
Ventral access from below the inguinal ligament; 1-2 injection sites.