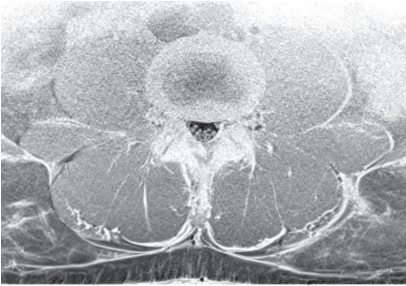
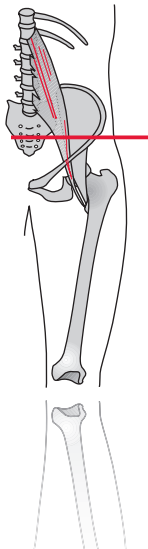
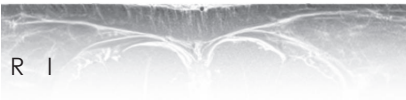


iliopsoas - m. psoas

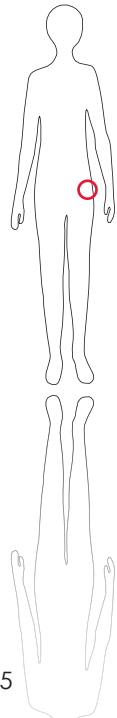**



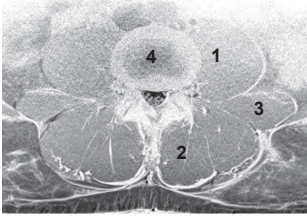
M R I



S c o u t



135



L e g e n d

1: M. iliopsoas 2: M. erector spinae 3: M. quadratus lumborum 4: Intervertebral disc L3-L4

O r i g i n

Corpora and transverse processes of first to fifth lumbar vertebrae

I n s e r t i o n

Trochanter minor femoris

I n n e r v a t i o n

Plexus lumbalis (L1-L4)

F u n c t i o n

Flexion, abduction and external rotation of hip joint

Control of Injection

Sonography or other imaging techniques (CT, MRI)

C o m m e n t

In patients with increased lumbolordosis, this is the leading muscle in hip flexion. Use 1-3 three injection sites with dorsal access.