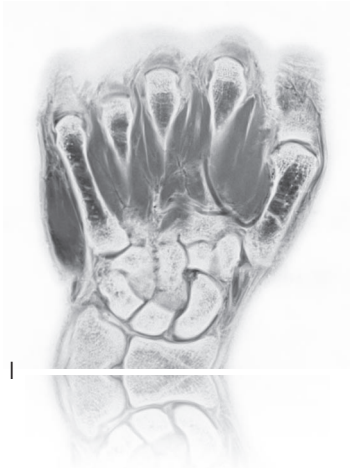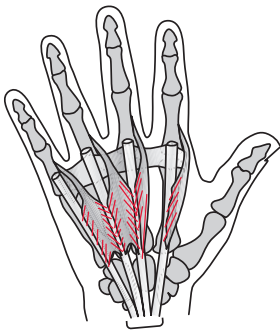


lumbricales

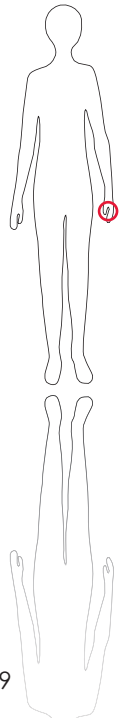
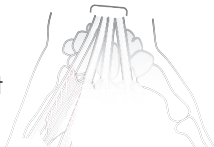**



M R I



S c o u t



129

O r i g i n
Tendons of flexor digitorum
profundus

I n s e r t i o n
Dorsal aponeuroses of the
four fingers

I n n e r v a t i o n
Deep branch of ulnar ner-
ve, median nerve

F u n c t i o n
Extend distal and middle
phalanges, flex metacar-
pophalangeal joints of the
four fingers

C o n t r o l o f I n j e c t i o n
Palpation is sufficient. In-
ject from dorsally.

C o m m e n t
One injection site per inte-
rosseus space.