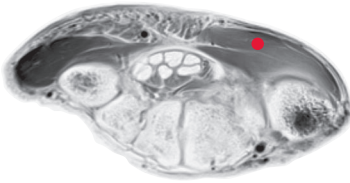
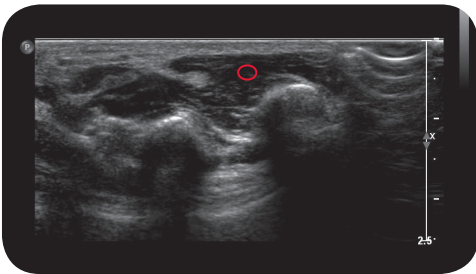


opponens pollicis

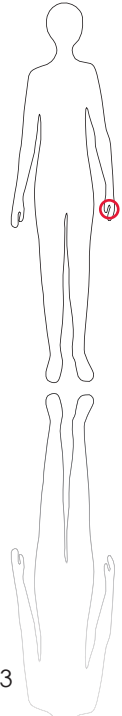
*



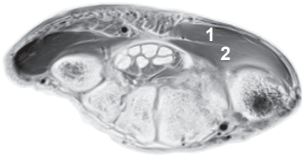
M R I



U l t r a s o u n d



133



L e g e n d
 1: M. opponens pollicis
 2: M. flexor pollicis brevis

O r i g i n
 Flexor retinaculum, tuber-
 cle of trapezium

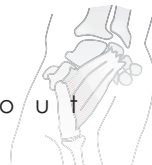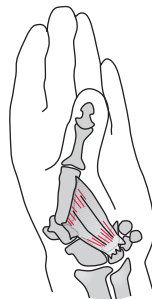
I n s e r t i o n
 Radial side of first meta-
 carpal bone

I n n e r v a t i o n
 Median nerve

F u n c t i o n
 Opposes carpometacar-
 pal joint (flexion, abduc-
 tion and slight rotation)

C o n t r o l o f I n j e c t i o n
 Palpation, sonography

C o m m e n t
 1 injection site



S c o u t