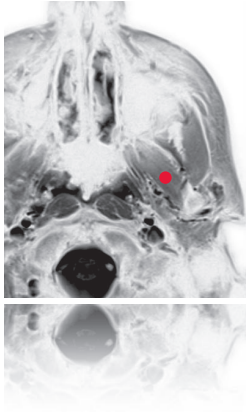
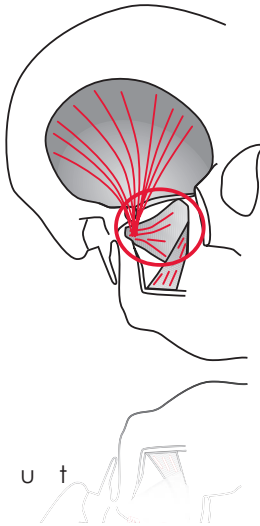


pterygoideus lateralis

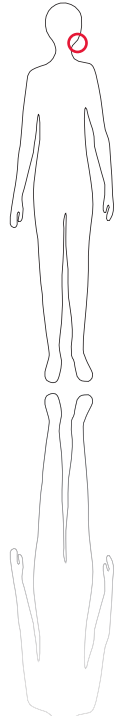
**



M R I



S c o u t



89

O r i g i n
Lamina lateralis of ptery-
goid process

I n s e r t i o n
Fovea pterygoidea of pro-
cessus condylaris mandi-
bulae

I n n e r v a t i o n
N. pterygoideus lateralis
division of trigeminal ner-
ve

F u n c t i o n
Opens jaws, moves man-
dible forward and from
side to side.

Control of Injection
EMG-controlled injection
has gained wide accep-
tance and is now con-
sidered state of the art.
Uncontrolled injection is
no longer acceptable.

C o m m e n t
Strongest jaw opener, in
synergy with digastricus
venter anterior; one injec-
tion site seems to be suffi-
cient.

