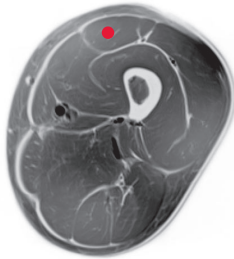




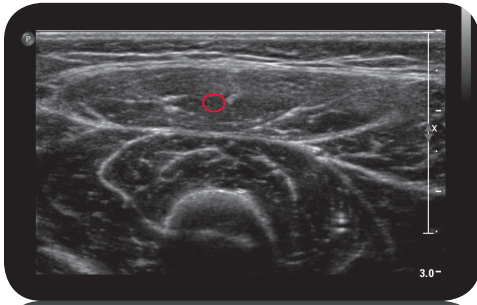
rectus femoris

**

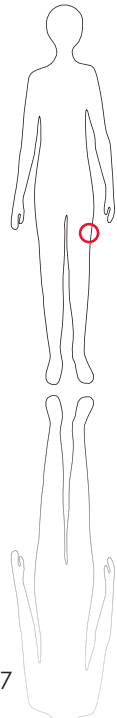
Cross Section



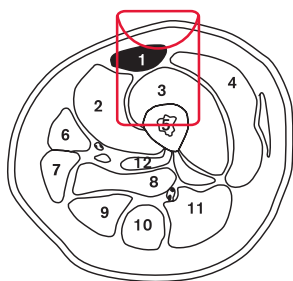
M R I



U l t r a s o u n d



147



L e g e n d

- 1: M. rectus femoris
- 2: M. vastus medialis
- 3: M. vastus intermedius
- 4: M. vastus lateralis
- 5: Femur
- 6: M. sartorius
- 7: M. gracilis
- 8: M. adductor magnus
- 9: M. semi-membranosus
- 10: M. semi-tendinosus
- 11: M. biceps femoris
- 12: M. adductor longus

O r i g i n

Anterior inferior iliac spine, supra-acetabular sulcus (upper rim of acetabulum)

I n s e r t i o n

Patellar ligament, tuberosity of tibia

I n n e r v a t i o n

N. femoralis (L2-L4)

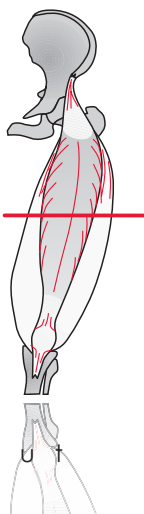
F u n c t i o n

Hip flexion, knee extension

Control of Injection
Sonography, electrical
stimulation, EMG

C o m m e n t

Often involved in hip flexion and knee extension spasticity; use 2-4 injection sites along the muscle.



S c o u t