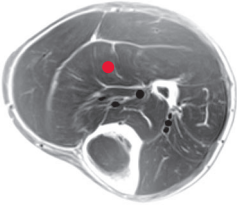


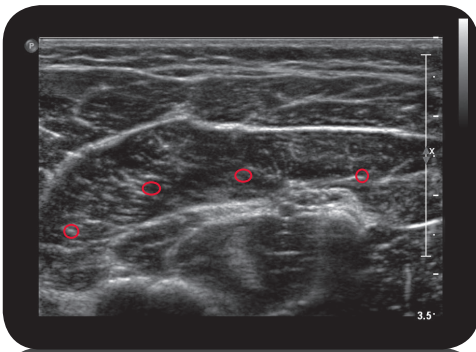
soleus

**

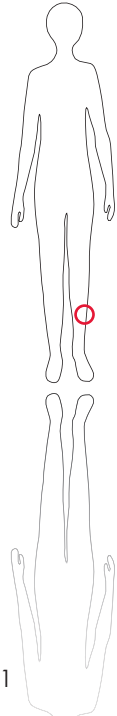
Cross Section



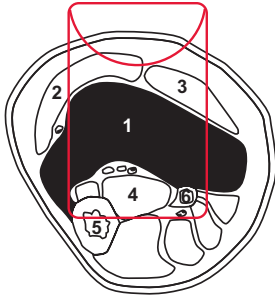
M R I



U l t r a s o u n d



161



L e g e n d

1: M. soleus 2: M. gastrocnemius medialis 3: M. gastrocnemius lateralis 4: M. tibialis posterior 5: Tibia 6: Fibula

O r i g i n

Dorsal surface of head of fibula, proximal third of fibula, tendinous arch of soleus, medial third of dorsal surface of tibia

I n s e r t i o n

Tuber calcanei by tendon calcaneus (Achilles tendon)

I n n e r v a t i o n

N. tibialis (L5-S1)

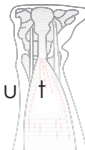
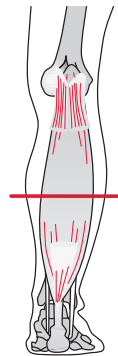
F u n c t i o n

Flexion of the foot at the ankle joint

Control of Injection Sonography, electrical stimulation

C o m m e n t

Tonically-innervated, mono-articular muscle. One to three injection sites



S c o u t