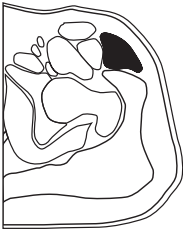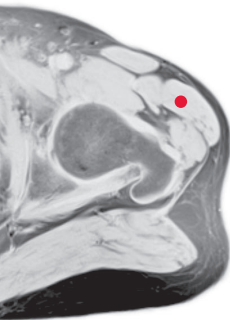


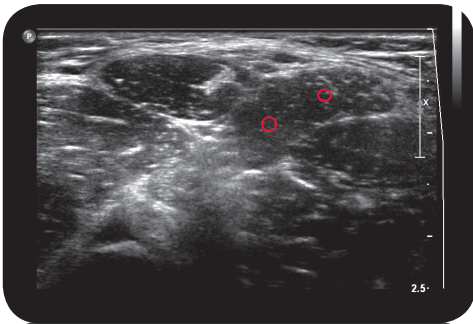
tensor fasciae latae



Cross Section

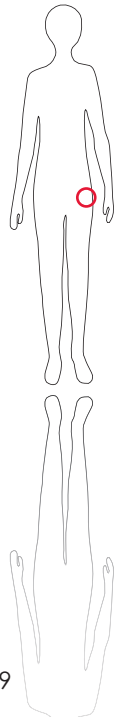


M R I

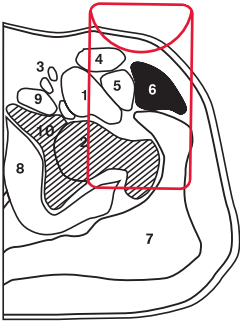


U l t r a s o u n d

*



139



L e g e n d

1: M. iliopsoas 2: Caput femoris 3: A./V./N. femoris 4: M. sartorius 5: M. rectus femoris 6: M. tensor fasciae latae 7: M. gluteus medius et maximus 8: M. obturatorius internus 9: M. pectineus 10: Fossa acetabuli

O r i g i n
iliac crest

I n s e r t i o n
iliotibial tract

I n n e r v a t i o n
N. glutealis sup. (L4-L5)

F u n c t i o n
flexes and medially rotates thigh, important for trunk stabilization

C o n t r o l o f I n j e c t i o n
Sonography, EMG

C o m m e n t
Can significantly contribute to thigh flexion, e.g. in windswept hip deformity