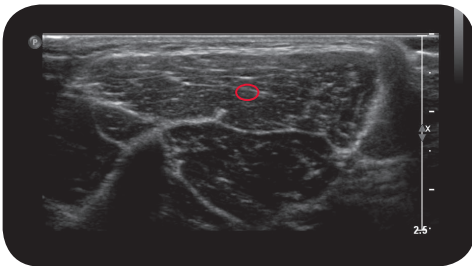
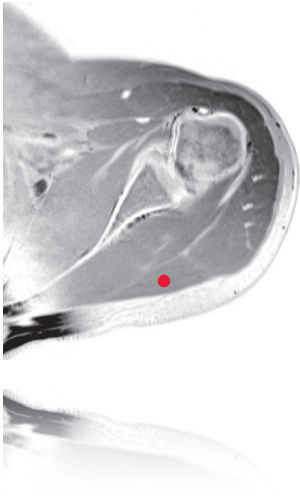


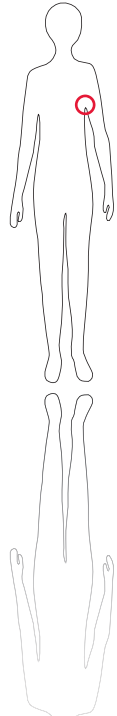
teres major

*

M R I



U l t r a s o u n d



95

O R I G I N

Dorsal surface of inferior scapular angle, medial third of lateral scapular margin

I N S E R T I O N

Christa tuberculi minoris humeri

I N N E R V A T I O N

N. thorakodorsalis or Nn. subscapulares (C5-C6)

F U N C T I O N

Adduction, extension and medial rotation of the humerus at the shoulder joint.

Control of Injection
Palpation, sonography,
EMG

C o m m e n t

A spastic teres major may impede the scapula's rotation, thus hindering elevation of the arm at the shoulder joint. This condition can be improved by injecting the muscle with BoNT.