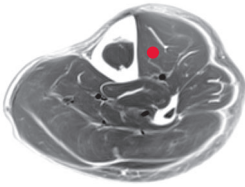
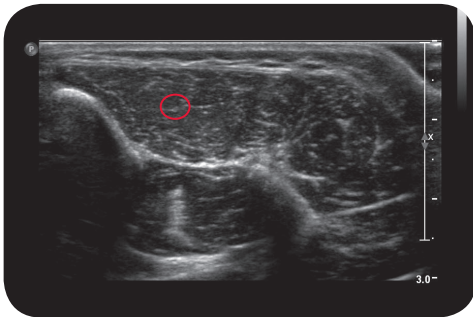

tibialis anterior

Cross Section

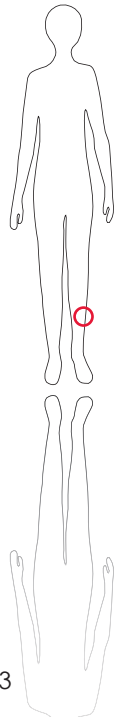


M R I

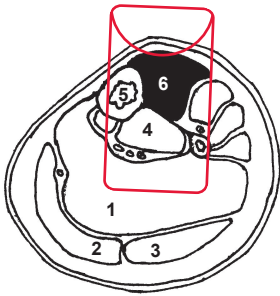


U l t r a s o u n d

*



163



L e g e n d

1: M. soleus 2: M. gastrocnemius medialis 3: M. gastrocnemius lateralis 4: M. tibialis posterior 5: Tibia 6: M. tibialis anterior

O r i g i n

Lateral condyle and lateral shaft of tibia, interosseous membrane, crural fascia

I n s e r t i o n

Medial cuneiform bone (medial and plantar surface)

I n n e r v a t i o n

N. peroneus profundus (L4-S1)

F u n c t i o n

Lifts medial side of foot; dorsiflexes ankle joint; supination of subtalar joint prepares initial heel contact during swing- to stance-phase transition

Control of Injection Sonography, electrical stimulation

C o m m e n t

Too high doses may cause weakening of dorsiflexion and deterioration of gait. 1-2 injection sites.